

Sonoelastography of the Median Nerve in Carpal Tunnel Syndrome in Correlation with Nerve Conduction Studies

D.R.Lasheen, S.M.Abdelmoneam, A.Y.El Shambaky and M.Y.Mahgoub

Rheumatology and Rehabilitation, Dept., Faculty of Medicine, Benha Univ., Benha, Egypt

E-Mail: Doaa.reyad@fmed.bu.edu.eg

Abstract

Sonoelastography is a novel ultrasound (US) tool of portraying the strain properties of biological tissue. The carpal tunnel syndrome (CTS) may cause structural and elastic distortion of the median nerve (MN). The aim of this study was to evaluate B- mode US and strain elastography in patients with CTS compared to healthy subjects and study their correlations with nerve conduction studies (NCS). Methods: This case-control study included 100 wrists of 57 patients clinically diagnosed as CTS and 110 non-diseased wrists of 55 apparently healthy controls. CTS patients underwent NCS. For both patients and control groups, the MN cross-sectional areas (CSA) at the wrist, the wrist/ forearm ratio (WFR) and the flattening ratio (FR) were obtained along with assessment of the MN echogenicity, and mobility. Elasticity of the MN was determined using strain elastography. Results: In the CTS patients, the MN at the wrist was highly significant stiffer ($p < 0.001$) than healthy controls. The MN CSA-D, WFR echogenicity, and mobility in the CTS group were highly significantly different from the control group ($p < 0.001$). The elastic ratio showed a statistically significant positive correlation with the MN distal motor latency ($r = 0.206$, $p = 0.040$) and a statistically significant negative correlation with the sensory amplitude ($r = -0.227$, $p = 0.023$) and sensory conduction velocity ($r = -0.312$, $p = 0.002$). There was a statistically significant positive correlation ($p < 0.05$) between the MN elastic ratio and the neurophysiological grades of NCS ($r = 0.252$, $p = 0.011$). Conclusion: In CTS, sonoelastography showed valuable correlations with NCSs. This study confirmed that sonoelastography might have a beneficial and practical value in CTS.

Key words: Strain elastography, carpal tunnel syndrome, neuromuscular ultrasound, nerve conduction studies

1. Introduction

Carpal tunnel syndrome (CTS) is a neuropathy caused by entrapment of the median nerve as it passes through the carpal tunnel. It accounts for 90% of all entrapment neuropathies [1], and though it is one of the most common nerve entrapment syndromes, there is no established standard for its diagnosis. It is a clinical diagnosis based on the history, clinical symptoms, and physical examination including positive provocative clinical tests. [2]

Nerve Conduction Studies (NCS) are used to support the diagnosis of CTS and to determine the severity of the disease. [3] However, NCSs have several limitations that raised the need to search for another tool less invasive and more convenient. [4]

Currently the ultrasound (US) is successfully used to support the diagnosis of CTS, where its sensitivity and specificities have been reported between 57–97.9% and 51–100% respectively. [5] US low cost, short study time, non-invasiveness, immediacy, and dynamic imaging makes it a convenient tool. Via direct visualization of the affected MN, US can identify reasons for secondary CTS and define structural variations, such as a persistent median artery, a bifid MN, or space-occupying lesions such as tenosynovitis and ganglion cysts. [6] The most commonly used US parameter for the diagnosis of CTS is the measurement of the cross-sectional area (CSA) of the MN at various levels within the carpal tunnel. [7]

Sonoelastography, a newer ultrasonographic property of nerves, has been assessed in some studies reporting increased stiffness of nerves afflicted by neuropathy. [8] Two main forms of elastography exist: strain elastography and shear wave elastography. Strain elastography measures tissue distortion due to pressure

in order to determine the stiffness of visible objects. [9] CTS may cause structural and elastic distortion of the MN.

The aim of this study was to evaluate B- mode US and strain elastography in patients with CTS compared to healthy controls and study their correlations with NCSs.

2. Subjects and methods

This case control study included 100 wrists of 57 patients clinically diagnosed as CTS according to the American Academy of Neurology Clinical Diagnostic Criteria of CTS [1]. All patients were recruited from the EMG Laboratory and the out-patients' clinic of the Rheumatology, Rehabilitation and Physical Medicine department. We also included 110 non-diseased wrists of 55 apparently healthy subjects of matched age and sex as a control group. The study was approved by the ethical committee of the Faculty of Medicine, Benha University. An informed consent was procured from all the patients and controls.

Inclusion criteria:

- Patients 20-60 years.
- Patients fulfilling the clinical criteria for idiopathic CTS.

Exclusion criteria:

- Patients <20 years or >60 years.
- History of neurological disorders that may produce numbness or paresthesia in the hand such as ulnar neuropathy, radiculopathy, polyneuropathy, myelopathy, or stroke that is confirmed by clinical examination.
- Patients with underlying morbidity that may cause CTS e.g., chronic renal failure, uncontrolled

diabetes, autoimmune diseases, other systemic disease, or use of contraceptive pills.

- Patients with prior corticosteroid injection or surgical intervention for CTS.
- Patients with a bifid median nerve (MN), a persistent median artery, or other anatomical variations of the MN, verified by ultrasound imaging.
- Patients with mass lesions such as lipomas, hemangiomas, hematomas, fibromas, and ganglion cysts that compress the MN causing CTS.

Examinations of the patients were performed consecutively on the same day by the same examiner. NCSs, B-mode US and US strain elastography were followed consecutively.

Nerve conduction studies

NCSs were performed using a Neurowerk EMG unit with a four-channel evoked potential/EMG measuring system (SIGMA Medizin-Technik GmbH Germany). NCSs were done according to the protocol recommended by the American Association of Electrodiagnostic Medicine. [10] It was done at room temperature.

Antidromic sensory median nerve and ulnar nerve conduction studies were recorded from digit II and digit V, respectively. Motor MN conduction studies with stimulation at the wrist and elbow and motor ulnar nerve conduction studies with stimulation at the wrist, above and below the elbow were recorded, both including F-waves.

The study was considered highly suggestive of an isolated CTS if the median studies were abnormal, showing marked slowing across the wrist (prolonged distal motor and sensory latencies). If the median studies are completely normal or equivocal, the comparison tests were done. [10] The severity of CTS was classified in our study according to Bland's classification system for CTS into six grades. [12]

Neuromuscular Ultrasound (NMUS) Evaluation

NMUS evaluation was performed using a linear high frequency 6-15 MHz probe on LOGIQ P9 (Korea) - ultrasound machine equipped with an elastography software. B-mode US was performed on the MN of patients and controls.

A standard protocol with optimization of scanning parameters was performed as suggested by Cartwright and Walker (2013). [11] All images were obtained with the subject laying supine on the bed, shoulders slightly abducted, elbows extended, and the forearms supinated. Wrists were evaluated in the neutral position with the palm up and the fingers semi-extended.

The machine settings were optimized, a large amount of gel was added, the weight of the probe was applied without additional pressure. The entire course of the MN in the carpal tunnel was assessed in both the transverse and longitudinal planes for variations, anomalies and pathologies that would exclude them from the study.

For each wrist, the MN cross-sectional areas (CSA) at the wrist and forearm and the flattening ratio (FR) were

obtained along with a subjective assessment of the MN echogenicity, and mobility.

The CSA-D of the MN was measured at the proximal inlet of the carpal tunnel at the scaphoid-pisiform level (the distal wrist crease). The CSA-P was measured in the forearm by tracing the MN 12 cm proximally. The CSA of the MN at the wrist and forearm were measured automatically by using the continuous tracing method of the nerve circumference, excluding the hyperechoic epineurial rim (i.e., tracing the inner margin of the epineurium of MN). The Wrist/ forearm ratio (WFR) was calculated dividing the CSA-D by CSA-P value. The flattening ratio (FR) was defined as the ratio of the nerve transverse axis to the antero-posterior axis and was assessed at the level of the pisiform bone. The Echogenicity was reported as: "Normal" if multiple fascicles could be seen, "Slightly reduced" if there were 2 or fewer fascicles, or "Decreased" if there were no fascicles. The mobility was evaluated at the proximal inlet of the carpal tunnel. The subjects were asked to make a fist slowly, ensuring that the fingers were fully flexed at the MCP and IP joints while the US transducer was held still. The grade of MN mobility was assessed as following: Grade 1: minimal movement of the MN in all directions, Grade 2: the MN moving freely in the transverse plane, but not diving deep in the flexor tendons, and Grade 3: the MN descending deeply and surrounded by the flexor tendons. The grade of MN mobility was measured twice and the higher grade was selected for analysis.[9]

Sonoelastography evaluation

Sonoelastographic assessments of the MN were performed with the same US machine and transducer. Positioning of the subjects and machine settings were adapted as the same for NMUS evaluation. Elastographic evaluation was undertaken according to the procedure suggested by Tatar et. al (2016): [5] The probe is positioned perpendicularly to take correct and reproducible measurements. Generous amount of gel was applied to the wrist, then the weight of the probe was applied without additional pressure. MN was visualized in the axial plane at the entrance of the carpal tunnel between the scaphoid and pisiform, using the B-Mode US. The MN was kept in the center of the screen.

Strain elastography was obtained by light compressions applied by the US probe. The elastograms were constructed automatically using the same optimal settings throughout the study. The elastogram appeared within a rectangular window as a translucent color coded, real-time image superimposed on the B-mode image. The color code indicated the relative stiffness of the tissues within the region of interest (ROI) and ranged from red (soft) to blue (hard). Green and yellow colors indicated medium elasticity.

Sonoelastographic images were obtained by means of repeated light compressions with the probe on the MN in the sagittal plane at the level of the carpal tunnel inlet. The probe was compressed and decompressed with approximately the same force and duration.

The measurements were done when more than half of the strain indicator was green. The screen was frozen at the decompression phase. The strain indicator indicated whether the displacement was sufficient to obtain local strains within the region of interest (ROI). Elliptical ROIs were drawn within the MN and again within the flexor carpi radialis (FCR), which was chosen as a reference tissue as it is outside the carpal tunnel. The ROI

was drawn to be the largest ellipse that would fit entirely within the structures. The elastic ratio (ER) is the ratio of strain distribution in the two selected regions of interests (ROI). Strain indices (SI) were calculated by the device automatically. Measurements were repeated 3 times, and the average strain ratio was recorded.

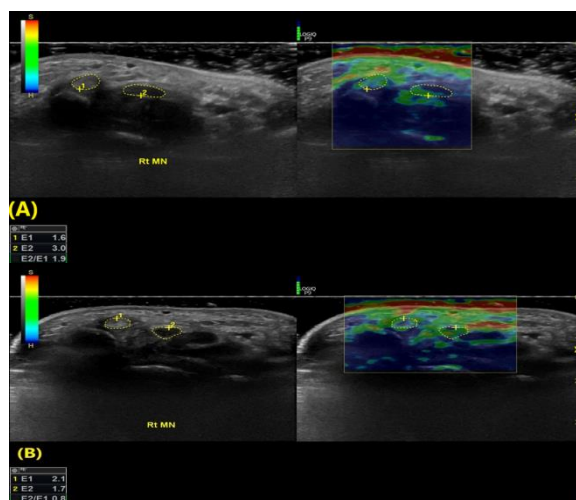


Fig. (1) B-mode ultrasonographic and sonoelastographic images of the median nerve in the transverse plane at carpal tunnel inlet. (A) 38-year-old female patient with mild carpal tunnel syndrome, (B) 25-year-old female healthy volunteer.

The displayed color spectrum indicates stiffness of the tissues, ranging from red (soft) to blue (hard). ROI 1 was put along reference tendon (flexor carpi radialis tendon). ROI 2 was put along the median nerve at carpal tunnel inlet. (E1) Elasticity index of reference tissue, (E2) Elasticity index of median nerve, and (E2/E1) elasticity ratio of median nerve at the carpal tunnel inlet.

Statistical analysis

Collected data was revised, coded, tabulated using a Statistical Package for Social Science (**IBM Corp. Released 2017. IBM SPSS Statistics for Windows, Version 25.0. Armonk, NY: IBM Corp.**). The Kolmogorov-Smirnov test was used to test the normal distribution of data. The difference in the NMUS and elastography parameters between CTS patients and healthy controls were elucidated by the Student's t-test. Mann Whitney Test (U test) was used to assess the statistical significance of the difference of a non-parametric variable between two study groups. Chi-Square test was used to examine the relationship between two qualitative variables. Fisher's exact test was used to examine the relationship between two qualitative variables when the expected count is less than 5 in more than 20% of cells. Correlations between parameters were evaluated using the Pearson correlation coefficient. P value <0.001 was considered highly significant (HS) while a P value >0.05 was considered non-significant.

3. Results

Demographic and clinical data among the studied groups; Table (1).

The Body mass index was the only parameter that was statistically significantly different ($p=0.037$) between the studied groups. Among the patients, the reversed Phalen test was positive in all wrists (100%) while the Tinel sign was positive in 76 wrists (76%).

Results of the electrodiagnostic studies

In 49 wrists (49%), the median routine NCS were completely normal. Comparative tests were done and found normal in 35 wrist (35%) and positive in 14 wrists (14%).

According to Bland's classification system for CTS (Bland, 2000), [12] the patients' wrists were classified into six grades: normal (35%), grade 1 (14%), grade 2 (6%), grade 3 (28%), grade 4 (6%), grade 5 (8%) and grade 6 (3%).

Neuromuscular ultrasound and Sonoelastographic findings in the studied groups:

Table (2) summarizes the mean values and the comparisons between the cases and the control groups of each NMUS parameter and the elastic ratio.

Correlations of NMUS and sonoelastographic parameters with nerve conduction studies parameters in the CTS group; Table (3)

Regarding the sonoelastographic parameters, the ER showed a statistically significant positive correlation ($p<0.05$) with the distal motor latency ($r=0.206$, $p=0.040$). The ER showed a statistically significant negative correlation ($p<0.05$) with the sensory amplitude ($r=-0.227$, $p=0.023$) and the sensory conduction velocity ($r=-0.312$, $p=0.002$). There was a statistically significant positive correlation ($p<0.05$) between the MN elastic ratio and the neurophysiological grades of NCS ($r=0.252$, $p=0.011$).

Table (1) Comparisons between the cases and the control group regarding the demographic data.

	Subjects				p
	Case n=57		Control n=55		
Age (years) mean ± SD	39	±9.8	35.7	±10.3	0.080
Sex; N, %	Males		3	5.3%	0.199
	Females		54	94.7%	
Weight (Kg) mean ± SD	83.1	±13.8	79.1	±15.6	0.157
Height (m) mean ± SD	1.61	±0.07	1.63	±0.08	0.146
BMI (Kg/m ²) mean ± SD	32.1	±5.0	29.9	±5.8	0.037 (S)
Symptom's duration (months) median (range)	12	(2-60)	-	-	-

SD: Standard deviation, N: number, p: Probability value, p<.05 = significant (S), p >.05 = insignificant, P <0.001 = high significant (HS), BMI: Body Mass Index

Table (2) Comparisons of the NMUS findings between the cases and the control group.

	Wrists				P	
	Case n=100		Control n=110			
Echogenicity: N, %	Normal	29	29%	108	98%	<0.001 (HS)
	slightly reduced	54	54%	2	2%	
	Reduced	17	17%	0	0%	
Mobility grades: N, %	1	22	22%	0	0%	<0.001 (HS)
	2	48	48%	12	11%	
	3	30	30%	98	89%	
CSA-D (mm ²): mean ± SD	14.6	4.6	9.0	1.9	<0.001 (HS)	
CSA-P (mm): mean ± SD	6.7	2.1	7.3	2.3	0.263	
WFR: median, range	2.12	0.87-5.66	1.25	0.75-2.20	<0.001 (HS)	
FR: mean ± SD	2.9	0.8	2.7	0.8	0.529	
Elastic ratio: mean ± SD	1.63	0.48	0.82	0.27	<0.001 (HS)	

NMUS, Neuromuscular ultrasound; CSA-D, cross sectional area distal at carpal tunnel; CSA-P, cross sectional area proximal at midforearm; WFR, Wrist/ forearm ratio; FR, Flattening ratio, SD: Standard deviation, N: number, P: Probability value, P<.05 = significant (S), P >.05 = insignificant, P <0.001 = high significant (HS).

Table (3) Correlations between NMUS parameters with electrodiagnostic studies parameters in the CTS group.

Parameters		CSA-D	CSA-P	WFR	Echogenicity	Mobility	FR
Distal motor latency	r	0.624	0.032	0.584	0.472	-0.428	0.259
	p	<0.001	0.754	<0.001	<0.001	<0.001	0.009
Motor Amplitude	r	-0.313	0.083	-0.339	-0.309	0.271	-0.179
	p	0.002	0.411	0.001	0.002	0.006	0.076
Motor conduction velocity	r	-0.357	-0.082	-0.294	-0.289	0.285	-0.054
	p	<0.001	0.420	0.003	0.003	0.004	0.597
Sensory latency	r	-0.112	-0.053	-0.095	0.028	0.068	-0.065
	p	0.269	0.600	0.347	0.782	0.501	0.522
Sensory Amplitude	r	-0.531	-0.116	-0.453	-0.366	0.393	-0.258
	p	<0.001	0.250	<0.001	<0.001	<0.001	0.009
Sensory Conduction Velocity	r	-0.576	-0.074	-0.506	-0.459	0.377	-0.265
	p	<0.001	0.462	<0.001	<0.001	<0.001	0.008
Neurophysiological grade	r	0.686	0.066	0.632	0.507	-0.421	0.310
	p	<0.001	0.514	<0.001	<0.001	<0.001	0.002

NMUS, Neuromuscular ultrasound; CSA-D, cross sectional area distal at carpal tunnel; CSA-P, cross sectional area proximal at midforearm; WFR, Wrist/ forearm ratio; FR, Flattening ratio, p: Probability value, p<.05 = significant (S), p >.05 = insignificant, P <0.001= high significant (HS), r: Pearson correlation coefficient.

4. Discussion

The advantages of US and the improvement of its image quality led to an increased adaptation of US studies in different musculoskeletal pathologies. US parameters such as the CSA and the WFR were used to support the diagnosis of CTS. [7] Sonoelastography has emerged as a tool in the study of CTS. Objectives of this study were to evaluate the role of B- mode US and strain elastography in patients with CTS and assess their correlations with NCS.

The most often reported US parameter in the diagnosis of CTS is the CSA of the MN at the proximal carpal tunnel [13]. We have found a noticeably higher MN CSA at the carpal tunnel inlet with a decreased echogenicity compared to healthy controls. Our results were consistent with previous studies [13-16] that revealed a larger MN CSA in CTS cases compared to healthy population. In addition, they reported a good agreement between the sonographic and electrodiagnostic findings. [17, 18]

In CTS, MN compression results in a localized circulatory disturbance with collapse of the blood-nerve barrier resulting in an increased endoneurial fluid pressure, with a resultant nerve edema and swelling and further impairing of the local blood flow. This is visualized as an increase in the CSA and decreased echogenicity of the MN. [19]

The second most commonly used parameter for evaluating the MN is the wrist/ forearm ratio (WFR) in which the CSA of the MN was measured at the wrist level and approximately 12 cm proximally from the wrist. We found that the WFR in CTS patients was increased compared to healthy controls. Our results were in parallel with previous studies. [14, 20, 21].

Hobson-Webb et al. (2008) reported that the WFR of 1.4 or more showed 100% sensitivity for detecting patients suffering from CTS.[20] On the other hand, some studies reported different results. [18, 22, 23]

The mechanical environment within the carpal tunnel affects the MN motion. Unlike the MN CSA, there has been a lack of consensus on the application of nerve mobility due to the complexity of dynamic analysis. [24] In our study, we found a restricted MN mobility in CTS patients compared to the controls. MN mobility correlated significantly with NCSs grading results. Similar results were reported in previous studies. [25, 26] Park et al., 2018 hypothesized that a reduced MN mobility in CTS may be related to fibrosis and adherence of the nerve to the flexor retinaculum. [25]

The flattening ratio (FR) of the MN was previously studied with controversial results. In our study, it was not found to be a useful discriminatory criterion in CTS patients that coincided with the results of Wong et al. (2002), Roll et al. (2011), and Chang et al., (2019).[27-29] Wong et al., 2002 suggested that the MN is a quite malleable structure, visibly changing in shape with movements of the flexor tendons resulting in the poor reliability of the FR measurements. [27] Our results were not consistent with those of Mallouhi et al.

(2006), Gonzalez-Suarez et al. (2019) and Perteau et al. (2019). [23, 30, 31]

On sonoelastographic evaluation of the MN in CTS patients using strain elastography, we found that the MN at the wrist was highly significantly stiffer than in the healthy controls. The ER correlated significantly with the results of NCSs.

Our results are in parallel with previous studies. [3, 5, 32-36] These studies have used strain elastography for the assessment of the MN and found that patients with CTS have a stiffer MN with larger CSA compared to the healthy population. Yoshi et al. (2017), reported significant correlations among NCSs, strain ratio, and CSA in CTS patients.[4]

Among the previous studies, only the study of Martin and Cartwright (2017) that reported no significant difference in the strain ratio between those with CTS and the controls and that the strain ratio did not correlate significantly with the traditional US parameters of CTS. [9]

In addition, Park et al. (2021) reported opposite results regarding the strain ratio.[37] They studied 95 wrists using strain elastography and shear wave elastography (SWE) diagnosed by EDX as CTS. The strain ratio showed no statistically significant difference between CTS patients and healthy controls and there was no significant correlation with CTS severity. However, the elasticity was significantly different between the two groups when evaluated by SWE. [37]

MN hardness detected by elastography reflects the histological quantitative changes in the MN. The pathophysiology of CTS is believed to be a combination of increased intracarpal tunnel pressure and ischemic injury of the MN. Increased pressure in the carpal tunnel causes stagnation or blockage of venous outflow and provokes venous congestion and hyperemia, followed by intra-neural edema. Long-term edema causes fibroblast invasion, which results in peri-neural thickening, nerve fiber changes and the accumulation of scar tissue inside the MN, which lead to increased stiffness of the nerve. [38] In addition, fibrosis of the MN in CTS is not only caused by intra-neural edema, but also changes in the oxidative stress and antioxidant defenses could be relevant to fibrosis through the disturbed signaling pattern in the tenosynovium and MN in patients with CTS.[32]

There are several limitations in our study; sonoelastography requires a meticulous technique in general, regardless of the sonoelastography mode. Various factors such as type of the ultrasound machine, orientation of the probe relative to the ROI, effect of structures adjacent to the ROI can lead to varying results. In our study, tendons were used as a reference point to calculate an ER. This may be a drawback as we assumed that the stiffness of the tendons remains relatively constant from a patient to a patient. Moreover, in a population sample such our patients and those of other researchers, the relation between the MN stiffness, demographic data and other NMUS parameters could not

be fully determined. Larger multicenter studies are recommended.

5. Conclusion

In CTS, sonoelastography showed valuable correlations with NCSs. Our study confirmed that sonoelastography might have a beneficial and practical value in CTS.

6. Reference

- [1] F.Kantarci . Median nerve stiffness measurement by shear wave elastography: a potential sonographic method in the diagnosis of carpal tunnel syndrome. *European Radiology*.vol.24(2),pp.434-440,2014.
- [2] Practice parameter for carpal tunnel syndrome (Summary statement).pdf,1993.
- [3] O.Ciloglu,and F.F.Gorgulu. Which Ultrasound Parameter Is More Accurate in the Diagnosis of Carpal Tunnel Syndrome: Cross-Sectional Area, Resistive Index, or Strain Ratio? *Am J Phys Med Rehabil*.vol.99(9),pp.842-846,2020.
- [4] Y.Yoshii,W.L.Tung,and T.Ishii, Measurement of Median Nerve Strain and Applied Pressure for the Diagnosis of Carpal Tunnel Syndrome. *Ultrasound Med Biol*.vol.43(6),pp.1205-1209,2017.
- [5] I.G.Tatar.Carpal tunnel syndrome elastosonographic strain ratio and cross-sectional area evaluation for the diagnosis and disease severity. *Med Ultrason*.vol.18(3),pp.305-11,2016.
- [6] H.Arslan.The efficiency of acoustic radiation force impulse (ARFI) elastography in the diagnosis and staging of carpal tunnel syndrome. *J Med Ultrason*.vol.45(3),pp.453-459,2018.
- [7] Y.Yoshii,C. Zhao, and P.C. Amadio, Recent Advances in Ultrasound Diagnosis of Carpal Tunnel Syndrome. *Diagnostics (Basel)*.vol.10(8),pp.122-150,2020.
- [8] C.P.Lin.Utility of Ultrasound Elastography in Evaluation of Carpal Tunnel Syndrome: A Systematic Review and Meta-analysis. *Ultrasound Med Biol*.vol.45(11),pp.2855-2865,2019.
- [9] M.J.Martin, and M.S. Cartwright, A Pilot Study of Strain Elastography in the Diagnosis of Carpal Tunnel Syndrome. *J Clin Neurophysiol*.vol.34(2),pp.114-118,2017.
- [10] C.K.Jablecki. Practice parameter Electrodiagnostic studies in carpal tunnel syndrome: Report of the American Association of Electrodiagnostic Medicine, American Academy of Neurology, and the American Academy of Physical Medicine and Rehabilitation. *Neurology*.vol.58(11),pp.1589-1592,2002.
- [11] M.S.Cartwright, and F.O. Walker, Neuromuscular ultrasound in common entrapment neuropathies. *Muscle & nerve*.vol.48(5): p. 696-704. 2013
- [12] J.D.Bland, A neurophysiological grading scale for carpal tunnel syndrome. *Muscle & Nerve: Official Journal of the American Association of Electrodiagnostic Medicine*.vol.23(8),pp.1280-1283,2000.
- [13] M.Sahebari.High-resolution ultrasonography of cross-sectional area of median nerve compared with electro-diagnostic study in carpal-tunnel syndrome. *Rheumatology Research*.vol.2(4),pp.127-131,2017.
- [14] D.Ažman,P. Hrabač, and V. Demarin, Use of multiple ultrasonographic parameters in confirmation of carpal tunnel syndrome. *Journal of Ultrasound in Medicine*.vol.37(4),pp.879-889,2018.
- [15] P.Roomizadeh.Ultrasonographic assessment of carpal tunnel syndrome severity: A systematic review and meta-analysis. *American journal of physical medicine & rehabilitation*.vol.98(5),pp.373-381,2019.
- [16] P.Aggarwal,V. Jirankali, and S.K. Garg, Accuracy of high-resolution ultrasonography in establishing the diagnosis of carpal tunnel syndrome. *ANZ journal of surgery*.vol.90(6),pp.1057-1061,2020.
- [17] T.Torres-Cuenca.Correlation of nerve conduction studies with findings of the ultrasound of the median nerve in patients with carpal tunnel syndrome. *Current Medical Imaging*.vol.12,pp.140-180,2021.
- [18] M.Ratasvuori.Ultrasonography for the diagnosis of carpal tunnel syndrome: correlation of clinical symptoms, cross-sectional areas and electroneuromyography. *Journal of Hand Surgery (European Volume)*.vol.2021,pp.175-319,2020.
- [19] H.Sugimoto,N. Miyaji, and T. Ohsawa, Carpal tunnel syndrome: evaluation of median nerve circulation with dynamic contrast-enhanced MR imaging. *Radiology*.vol.190(2),pp.459-466,1994.
- [20] L.D.Hobson-Webb.The ultrasonographic wrist-to-forearm median nerve area ratio in carpal tunnel syndrome. *Clin Neurophysiol*.vol.119(6),pp.1353-7,2008.
- [21] S.Billakota, and L.D. Hobson-Webb, Standard median nerve ultrasound in carpal tunnel syndrome: A retrospective review of 1,021 cases. *Clinical neurophysiology practice*.vol.12,pp.188-191,2017.

- [22] L.H.Visser,M.H. Smidt, and M.L.Lee, Diagnostic value of wrist median nerve cross sectional area versus wrist-to-forearm ratio in carpal tunnel syndrome. *Clin Neurophysiol*.vol.119(12),pp.2898-2899,2008.
- [23] C.B.Gonzalez-Suarez.Diagnostic accuracy of ultrasound parameters in carpal tunnel syndrome: additional criteria for diagnosis. *Journal of Ultrasound in Medicine*.vol.38(11),pp.3043-3052,2019.
- [24] I. N.Lo,P.-C. Hsu, and Y. C. Huang, The effect of anti-adhesion gel on median nerve mobility and early clinical outcome in carpal tunnel release. *Journal of Hand Surgery (European Volume)*, .vol.46(3),pp,316-318,2021.
- [25] G. y.Park,Usefulness of ultrasound assessment of median nerve mobility in carpal tunnel syndrome. *Acta Radiologica*.vol.59(12),pp.1494-1499,2018.
- [26] V.J.Schrier.Median nerve transverse mobility and outcome after carpal tunnel release. *Ultrasound in medicine & biology*.vol.45(11),pp.2887-2897,2019.
- [27] S.Wong.Discriminatory sonographic criteria for the diagnosis of carpal tunnel syndrome. *Arthritis & Rheumatism: Official Journal of the American College of Rheumatology*.vol.46(7),pp.1914-1921,2002.
- [28] S.C.Roll,J. Case-Smith, and K.D. Evans, Diagnostic accuracy of ultrasonography vs. electromyography in carpal tunnel syndrome: a systematic review of literature. *Ultrasound in medicine & biology*.vol.37(10),pp.1539-1553,2011.
- [29] Y. W.Chang.Ratio and difference of the cross-sectional area of median nerve to ulnar nerve in diagnosing carpal tunnel syndrome: a case control study. *BMC medical imaging*.vol.19(1),pp.1-9, 2019.
- [30] A.Mallouhi.Predictors of carpal tunnel syndrome: accuracy of gray-scale and color Doppler sonography. *AJR Am J Roentgenol*.vol.186(5),pp.1240-5,2006.
- [31] M.Pertea.Ultrasonography of the Median Nerve in the Carpal Tunnel Syndrome Diagnosis. in *E-Health and Bioengineering Conference (EHB)*.vol.12,pp.122-150,2019.
- [32] G.Orman.Ultrasound elastographic evaluation in the diagnosis of carpal tunnel syndrome: initial findings. *Ultrasound Med Biol*.vol.39(7),pp.1184-9,2013.
- [33] H.Miyamoto.Carpal Tunnel Syndrome: Diagnosis by Means of Median Nerve Elasticity—Improved Diagnostic Accuracy of US with Sonoelastography. *Radiology*.vol.270(2),pp.481-486,2014.
- [34] R.Asadov.The effectiveness of ultrasonography and ultrasonographic elastography in the diagnosis of carpal tunnel syndrome and evaluation of treatment response after steroid injection. *Eur J Radiol*.vol.108,pp.172-176,2018.
- [35] E.Karatay,O. Turkoglu, and B. Mansiz-Kaplan, Karpal tünel sendromunda median sinir sertliği ölçümlerini kullanarak real-time strain elastografinin tanısal etkinliğinin değerlendirilmesi. *Cukurova Medical Journal*.vol.45(4),pp.1276-1282,2020.
- [36] A.Mahmoud.The Role of Sonoelastography in Diagnosis and Grading of Patients with Carpal Tunnel Syndrome. *The Medical Journal of Cairo University*.vol.89,pp.2203-2211,2021.
- [37] E.J.Park.Comparison of the Diagnostic Performance of Strain Elastography and Shear Wave Elastography for the Diagnosis of Carpal Tunnel Syndrome. *J Ultrasound Med*.vol.40(5),pp.1011-1021,2021.
- [38] M.Cingoz.Evaluation of median nerve by shear wave elastography and diffusion tensor imaging in carpal tunnel syndrome. *Eur J Radiol*.vol.101,pp.59-64,2018.